

Iliofemoral Venous Stenting for Patients with Chronic Post-thrombotic Venous Occlusive Disease

Sherif Essam Eldin Tawfik, MD; Abdelrahman Mohamed Salem, MD

Department of Vascular Surgery, Faculty of Medicine, Ain Shams University, Cairo, Egypt

ABSTRACT

Introduction: Post-thrombotic syndrome resulting from iliofemoral venous occlusive disease constitutes a magnificent burden to the patient, affecting his functionality. For decades the traditional treatment for chronic iliofemoral venous occlusive disease has been mainly conservative lines of treatment. Unfortunately this conservative treatment did not improve the functional outcome in the vast majority of patients. In our study we aimed at studying the effect of interventional lines of treatment in the form of endovascular iliofemoral venous stenting in patients with chronic post thrombotic syndrome with special emphasis on clinical and functional outcomes after such relatively new line of treatment. **Methods:** Between March 2013 and January 2015, we enrolled 23 patients with chronic post-thrombotic iliofemoral venous occlusive disease in our prospective interventional clinical study. Our patients were treated by endovascular balloon dilatation and stenting for the affected iliofemoral venous segment through femoral or popliteal vein access. our primary end points were primary and assisted primary patency at 24 months follow up, while secondary end points were clinical and functional outcomes as measured by the Villalta scale and venous disability score (VDS). **Results:** Data was obtained for 23 patients. All of them presented with unilateral lower limb Post-thrombotic manifestations. The mean duration of post thrombotic symptoms was 17.5 months. The baseline CEAP classification of the 23 patients was, C4 (21.7%), C5 (43.5%), and C6 (34.8%). Immediate technical success was achieved in 19(82.6%) patients. Stenting was attempted in all 19 patients. Analysis of the clinical outcome at 24 months according to the Villalta scale showed a mean Villalta score difference of 15.04, $t = 7.87$, $p < 0.00001$ (highly significant). Analysis of the functional outcome at 24 months according to the venous disability score (VDS) using the Wilcoxon signed rank test showed a mean score difference of 0.84, $z = 3.823$, $p = 0.00014$ (highly significant). Primary, and assisted primary patency rates were calculated using survival analysis with the Kaplan-Meier method. Our primary patency rate was 89.4% at 24 months, while our assisted primary patency rate was 100% at 24 months. **Conclusion:** This study successfully demonstrates a durable 2-years primary, and assisted primary patencies as well as sustained symptomatic relief and significant improvement in functional outcome with the majority of patients able to resume their activities of daily living. Therefore, aggressive endovascular therapy provides durable patency as well as significant clinical and functional improvement in patients with chronic post-thrombotic iliofemoral venous occlusive disease.

Keywords: iliofemoral; post thrombotic; venous stenting

INTRODUCTION

Post-thrombotic syndrome (PTS) represents a significant cause of chronic morbidity among patients with iliofemoral venous thrombotic occlusive disease.¹ Natural history studies of iliofemoral deep venous thrombosis (DVT) treated with anticoagulation alone have shown that, at five years, over 90% of patients have venous insufficiency, 15% have experienced venous ulceration, 15% have developed venous claudication, and 40% have restricted ambulation.² Many studies demonstrate hemodynamic impairment and reduced quality of

life.³ The pattern of spontaneous recanalisation after DVT varies according to the affected anatomical segment. While recanalisation occurs in up to 90% of the femoro-popliteal veins after one year, this is rarely the case (<5%) after iliofemoral thrombosis.⁴ Chronic obstruction of the iliac vein, being the common outflow tract of the lower limb, results in severe symptoms because of poor compensation by collateral formation.⁵ The pathophysiology of post-thrombotic venous insufficiency is ambulatory venous hypertension, defined as elevated venous pressures during exercise,⁶ which is particularly severe when both valvular incompetence and

venous obstruction coexist. In addition, recent studies suggest that patients with high proximal (iliac or proximal femoral vein) DVT have significantly worse PTS severity than those with distal or popliteal vein DVT.⁷ Until recently, recommendations and standard of care for this subset of venous occlusive disease was largely the same as for DVT occurring more distally i.e.: systemic anticoagulation alone. However, as surgical methodology has advanced and catheterization technology has improved, percutaneous endovenous stenting has emerged during the last decade as the method of choice to treat chronic iliofemoral venous outflow obstruction. It has replaced bypass surgery as the primary treatment.⁵

There are few reports in the literature analyzing the effect of endovascular treatment in patients with severe symptoms due to venous outflow post-thrombotic chronic occlusions.⁸ The aim of this study was to assess the mid-term patency and clinical outcome after recanalisation and stenting of chronically occluded iliofemoral venous segments among patients with chronic post-thrombotic venous occlusive disease.

PATIENTS AND METHODS

From March 2013 to January 2015, 23 consecutive patients with chronic post thrombotic iliofemoral venous occlusive disease were enrolled in our prospective clinical interventional study. This study was conducted at Ain Shams University hospitals. Our inclusion criteria were patients who presented with manifestations of chronic post thrombotic venous occlusive disease in the form of lower limb persistent swelling, pain, or ulcerations. Exclusion criteria were clinical evidence and/or duplex evidence of a recent acute DVT, history of previous thrombolysis or stenting to the affected iliofemoral venous segment, or history of previous trauma, surgery, venous catheter insertion or recreational drug injection into the iliofemoral venous segment. Limbs with extensive obstructive lesions and with poor inflow or outflow were also excluded. We considered "extensive obstructive lesions and poor inflow or outflow" when inferior vena cava was affected or when deep femoral, popliteal, and distal veins were simultaneously affected, and inflow was insufficient to maintain stent patency.

Patients were clinically classified at enrollment according to the CEAP classification (Figure 1) according to the Reporting Standards of the International Society of Cardiovascular Surgery (ISCS)/Society for Vascular Surgery (SVS).⁹ The venous disability score (VDS)¹⁰, and the Villalta scale¹¹ (Figure 2,3) were also used to assess and compare the clinical and functional outcome over the follow up period.

Class	Signs
0	No visible or palpable signs of venous disease
1	Telangiectases, reticular veins, malleolar flare
2	Varicose veins
3	Edema without skin changes
4	Skin changes ascribed to venous disease (pigmentation, venous eczema, lipodermatosclerosis)
5	Skin changes as above with healed ulceration
6	Skin changes as above with active ulceration

Fig. 1: CEAP classification; The "C" clinical categories

0 = asymptomatic
1 = symptomatic but able to carry out usual activities* without compressive therapy
2 = can carry out usual activities* only with compression and/or limb elevation
3 = unable to carry out usual activities* even with compression and/or limb elevation

*Usual activities = patients activities *before* onset of disability from venous disease.

Fig. 2: Venous disability score

Symptoms/clinical signs	None	Mild	Moderate	Severe
Symptoms				
Pain	0 points	1 point	2 points	3 points
Cramps	0 points	1 point	2 points	3 points
Heaviness	0 points	1 point	2 points	3 points
Paresthesia	0 points	1 point	2 points	3 points
Pruritus	0 points	1 point	2 points	3 points
Clinical signs				
Pretibial edema	0 points	1 point	2 points	3 points
Skin induration	0 points	1 point	2 points	3 points
Hyperpigmentation	0 points	1 point	2 points	3 points
Redness	0 points	1 point	2 points	3 points
Venous ectasia	0 points	1 point	2 points	3 points
Pain on calf compression	0 points	1 point	2 points	3 points
Venous ulcer	Absent			Present

Fig. 3: Villalta Scale

Our preoperative imaging protocol was by duplex ultrasound and ascending spiral CT venography which was performed with contrast injection through the superficial dorsal veins of the foot with a tourniquet applied at mid-calf to direct the contrast medium to go through the deep veins of the leg. The occlusive lesion was considered post thrombotic if the patient had a previous occurrence of deep vein thrombosis diagnosed with duplex ultrasound and had subsequently been treated by anticoagulation; or findings on CT venography (iliofemoral venous occlusion, stenosis or collaterals) indicating previous deep vein thrombosis. One of the prerequisites for our procedure was a CT venography evidence of a good adequate access site for our sheath which is either a patent superficial femoral vein in the upper or mid-thigh segment or a patent popliteal vein.

The procedure was done under general anesthesia at an operative suite with a mobile C-arm with vascular imaging capabilities. Vein access was gained under ultrasound guidance either through a patent compressible femoral vein in upper or mid-thigh or through a patent compressible popliteal vein while the patient is in the supine position. An introducer 8Fr sheath was inserted percutaneously under ultrasound guidance followed by intravenous administration of sodium heparin at a dose of 100 IU/Kg, then a venography was done by injecting non-ionic contrast media (Ultravist®300, Bayer) diluted with 0.9% saline at a ratio of 1:1 through the sheath to get an overview of the pathologically stenosed or occluded venous segment and the collaterals around the occluded segment. An anteroposterior and oblique views were taken to get a clear idea of the intended pathway for the guidewire into the main iliac veins to avoid misleading pathways into surrounding collaterals. Traversing the pathologically affected veins was achieved by the aid of a hydrophilic angled tip guidewire 0.035 inch (Radiofocus® Glidewire® Terumo corporation, Japan) or a 0.018 inch steerable guidewire (V-18™, ControlWire™, Boston scientific corporation, USA) with the support of an angiographic angled tip catheter (BERN, Imager™, Boston scientific corporation, USA) or a straight support catheter (Rubicon™, Boston scientific corporation, USA).

After traversing the occluded iliac vein segment, the angiographic catheter or the support catheter was used to do a control angiography to verify the true passage to the inferior vena cava (IVC) then guidewire exchange to a super stiff guidewire (Amplatz Super Stiff™ guidewire, Boston scientific corporation, USA). Balloon dilatation was attempted using a high pressure 12mmx80mm balloon (Mustang™ Balloon Dilatation Catheter, Boston scientific corporation, USA) to the iliac veins and common femoral vein, then a 14mmx40mm balloon (Advance® ATB PTA Dilatation Catheter, COOK® Medical incorporation, USA) was used to dilate the common iliac vein. Balloon inflation was maintained for at least 1 minute at nominal inflation pressure. Following balloon dilatation, another control angiography was done prior to stenting to visualize the confluence of the common iliac vein with IVC proximally and to visualize the confluence of the deep femoral vein with the common femoral vein distally. Our stenting strategy was to stent the entire affected segment starting proximally from inside the lower end of the inferior vena cava down to the external iliac vein or even further down to the common femoral vein above the deep femoral vein ostium liberally crossing the inguinal ligament in case where the common femoral vein is affected. Adequate overlap between the deployed stents was ensured to avoid foreshortening during post stent dilatation and to avoid having skipped non-stented areas in the treated vein segment. For Vein stenting we used (WALLSTENT™ Endoprothesis, Boston scientific corporation, USA). The choice of stent diameter was according to the discretion of the operator and was usually between 16-18mm in the common iliac vein segment and 12-14mm in the common femoral and external iliac vein segment. The large diameter WALLSTENT necessitated that we change the 8Fr sheath to a larger 10Fr sheath. The final step after stenting was to do a post stent dilatation for 1 minute to ensure good stent to vein wall apposition and to prevent future stent migration. Completion venography was done at the end of the procedure to visualize the treated segment to ensure free flow of contrast through the stented segment up to the IVC together with the disappearance of the collaterals and ensure that there are no residual stenotic areas (Figure 4).

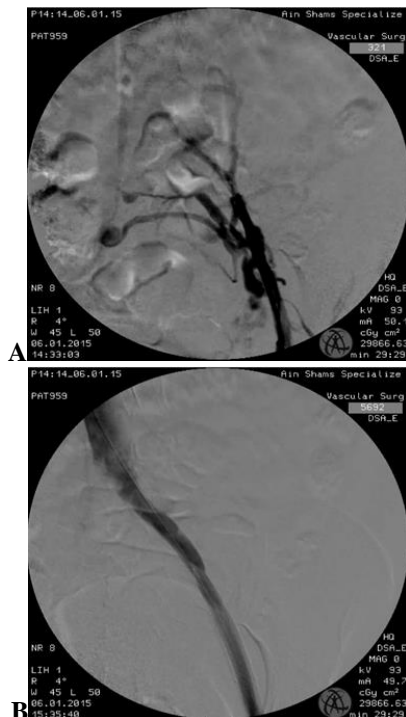


Fig. 4: (A)Pre and (B)post intervention angiography showing free flow of contrast through the stented segment up to the IVC together with the disappearance of the collaterals

Immediately after the procedure the patient was kept on therapeutic low molecular weight heparin (Enoxaparin sodium) according to body weight at a dose of 1mg/Kg subcutaneous injection every 12 hours for at least 5 days with overlapping shift to oral vitamin K antagonists for a target International Normalization Ratio (INR) of 2.0 to 3.0 monitored at least once every month for 2 years. Follow up was done post-procedure at 1 month, and every 6 months thereafter over the follow up period throughout the study by clinical evaluation according to Villalta scale, and Venous Disability Score (VDS). Duplex ultrasound examination was performed at each follow up visit looking for visible narrowing >50% of the flow lumen or localized increase in flow velocities along the stented segment or abnormal waveform response to respiratory phasity. CT venography was only done in case of recurrence of symptoms with duplex findings suggesting restenosis during the follow up visits. Our primary end points were primary, assisted primary patency of the stented venous segment while the secondary end points were improvement in the

Villalta scale and Venous Disability Score (VDS) over the follow up period together with 30 day morbidity and mortality.

RESULTS

Data was obtained for 23 patients (23 limbs) who underwent stenting for post-thrombotic iliofemoral venous occlusive disease during the study period. Demographic and clinical features of the study group are shown in (Table 1). The group included 16(69.5%) males, with a mean age of 34.2 years (range: 24-60 years). All 23 patients presented with unilateral lower limb Post-thrombotic manifestations. The left leg was the affected limb in 20 patients, with right to left ratio of (1:6.6). None of the 23 patients had a previous IVC filter placement. Three patients had diabetes (13%), while five patients were hypertensive (21.7%). The mean duration of post thrombotic symptoms was 17.5 months (range 6-48 months).

The baseline CEAP classification of the 23 patients (Table 2) was, Five (21.7%) patients were C4 presenting with pigmentation and lipodermatosclerosis, Ten (43.5%) patients were C5 presenting with healed venous ulcers, while Eight (34.8%) patients were C6 presenting with active venous ulcers (Figure 5). Regarding the anatomical extent of the disease based upon CT venography, we had 15(65.2%) patients with common and external iliac vein involvement, while 8(34.8%) patients had common, external iliac veins and common femoral vein involvement. Regarding the pathology, 19 (82.6%) patients had obstruction only (Po) while four(17.4%) patients had reflux and obstruction (Pr,o).

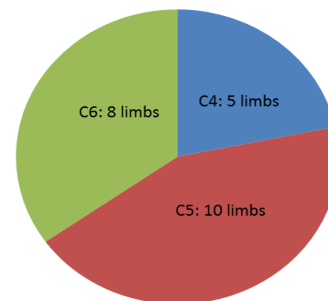


Fig. 5: The baseline initial presentation of 23 limbs according to the C part of CEAP classification

Primary vein access was achieved through the femoral vein in mid-thigh in 15(65.2%) patients and through the popliteal vein in 8(34.8%) patients (Table 3).

Immediate technical success was achieved in 19(82.6%) patients with remaining four technical failures out of the 23 patients (Table 4). Our technical failures were due to failure of crossing the chronically occluded femoral vein into the iliac veins, with either a preferential passage of the guidewire into large collaterals emerging just before the occlusive lesion or due to subadventitial passage of the guidewire with the resultant perforation. Perforation occurred in two out of the four failures and was self-limited and disappeared within minutes during the procedure without any undesired consequences.

Stenting of the common and external iliac veins after balloon dilatation was attempted in 15 patients, while extending our stents further down to involve the common femoral vein was needed in four patients. This makes a total of 19 patients who had stents deployed in whom there was a technical success of the procedure after excluding the four technical failures (Table 4).

Procedure related complications such as access site hematomas, infection, arteriovenous fistulae, retroperitoneal bleeding, or contralateral iliac vein thrombosis was not encountered in any of our 23 patients Apart from the two self-limited perforations mentioned earlier (Table 4).

Analysis of our clinical outcome was done by comparing the Villalta scale before and at one month after the procedure. Paired "T test" was used to test our results against the Null hypothesis using a significance level of ≤ 0.05 , and the results showed a mean Villalta score difference of 9.57, $t = 8.02$, $p < 0.00001$. These results, demonstrated that the difference between before and one month post intervention Villalta scale, was highly significant.

Because we think that the Villalta scale results would also improve over longer time follow up due to the nature of some of its clinical components which needs longer time follow up to improve like paresthesia, skin induration, and hyperpigmentation, we compared the results of the Villalta scale again before and at 24 months after the procedure. Again Paired "T test" was used to test our results against the Null hypothesis using a significance level of ≤ 0.05 , and the results showed a mean Villalta score difference of 15.04,

$t = 7.87$, $p < 0.00001$. These results, again demonstrates that the difference between before and at 24 months post intervention Villalta scale, was highly significant.

To further assess postoperative functional outcome, the venous disability score (VDS) which is a part of a disease-specific quality-of-life measurement tool, was calculated. Comparison between the VDS before and at 24 months after the procedure was plotted on pie-chart and compared using Wilcoxon signed rank test.

Venous disability scores demonstrated excellent functional recovery at 24 months follow up. All 19(82.6%) patients, in whom the procedure was technically successful, were able to perform their baseline activities without requiring compression therapy or leg elevation, VDS score 1. In the four patients in whom the procedure initially technically failed, one patient (4.4%) required ongoing compression or intermittent leg elevation to perform usual daily activities, VDS score 2. The remaining three patients (13%) remained significantly debilitated and unable to perform baseline activities despite using compression and/or elevation, VDS score 3 (Figure 6).

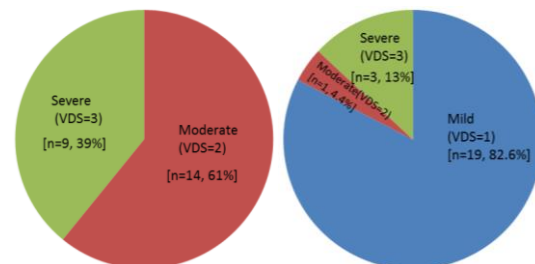


Fig. 6: Pie chart representing the Venous Disability Score (VDS) before then at 24 months after the procedure

The Wilcoxon signed rank test was used to compare the venous disability score before and at 24 months after the procedure and the results showed a mean score difference of 0.84, $z = 3.823$, $p = 0.00014$, the result is significant at $p \leq 0.05$.

Follow-up duplex performed on these patients revealed patent stents after initial stent placement in all 19 technically successful limbs at 1 month follow up, however there was one patient who had $>60\%$ in-stent stenosis at 6 months and another patient had $>80\%$ in-stent stenosis at 12 months. Those duplex findings of in-stent stenosis were

accompanied by a deterioration of clinical and functional outcomes in these two patients at these follow up time points as evidenced by a rise in the Villalta and the VDS scores. Those two patients had a re-intervention to maintain the patency of these stents and to restore the clinical and functional outcome. The re-intervention in those two patients was in the form of balloon dilatation only which yielded an immediate satisfactory angiographic result and an improvement of both clinical and functional outcome over the rest of the follow up period up to 24 months. Notably, these two events of in-stent stenosis occurred in patients who had stents extending from the common iliac veins down to involve the common femoral vein. Primary, and assisted primary patency rates as defined by the reporting standards of the ISCVS/SVS, were calculated using survival analysis with the Kaplan-Meier method. Our primary patency rate was 89.4% at 24 months, while our assisted primary patency rate was 100% at 24 months (Figure 7,8).

Table 1: Demographic data

Characteristics	N (%)
Age	Mean 34.2 years, range 24-60 years
Gender Male	16 (69.5%)
Female	7(30.5%)
Bilaterality	
Right leg	3 (13%)
Left leg	20(87%)
Both	0
Ratio Rt:Lt	1:6.6
Duration of PTS symptoms	17.5 months, range 6-48 months
Previous IVC filter placement	Zero
Diabetes	3(13%)
Hypertension	5(21.7%)

Table 2: Clinical presentation according to CEAP classification

CEAP classification	N (%)
C4	5(21.7%)
C5	10(43.5%)
C6	8(34.8%)
E (Etiology) Post-thrombotic	23(100%)
A (Anatomy) Common and external iliac vein only	15(65.2%)
Common, external iliac, and common femoral vein	8(34.8%)
P (Pathology) Occlusion (Po)	19(82.6%)
Reflux and occlusion (Pr,o)	4(17.4%)

Table 3: Primary vein access

Vein	N(%)
Femoral vein mid thigh	15(65.2%)
Popliteal vein	8(34.8%)

Table 4: Immediate technical success, veins stented, and procedure related complications

	N(%)
Immediate technical success	19(82.6%)
Technical failure	4(17.4%)
Stenting common and external iliac veins	15(65.2%)
Stenting common, external iliac, and common femoral veins	4(17.4%)
Procedure related complications	zero

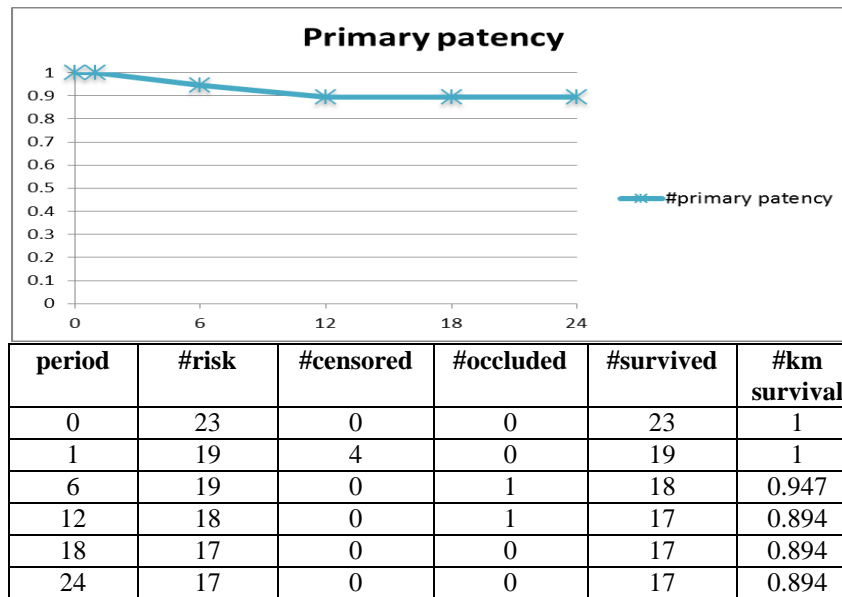


Fig. 7: Kaplan Meier curve for primary patency

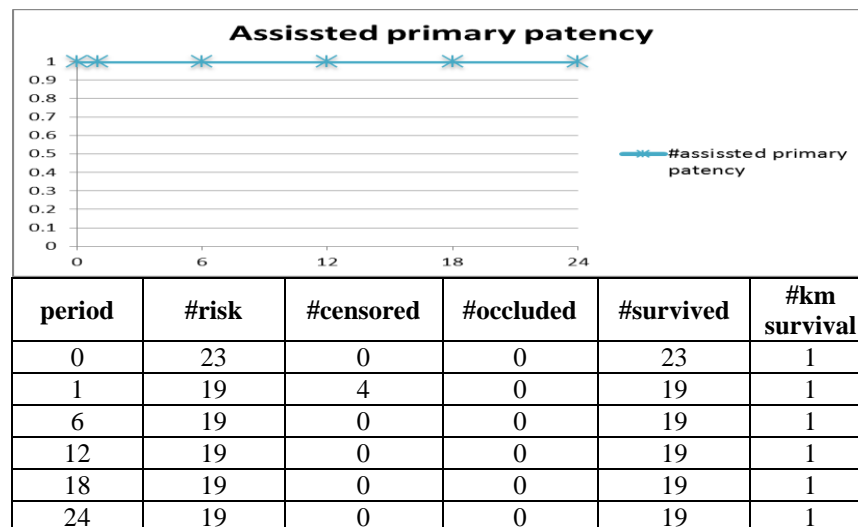


Fig. 8: Kaplan Meier curve for assisted primary patency

DISCUSSION

The long-term sequelae of iliofemoral thrombosis manifesting as post-thrombotic syndrome are associated with significant ongoing disability and detrimental effects on quality of life.²

Over the previous decade, endovascular treatment options including angioplasty and stenting have been incorporated into treatment paradigms based on the premise that

anticoagulation alone may yield unacceptable rates of chronic morbidity, especially in the setting of underlying untreated iliac vein stenosis. Although numerous previous reports have primarily focused on the technical success and durability of endovascular intervention,¹ few have addressed functional outcomes in these otherwise relatively young, healthy, active patients.

Although prior reports have demonstrated symptomatic improvement in both pain and edema, such studies have seldomly examined

mid-term disability as measured by one's performing activities of daily living as measured by the venous disability score (VDS), perhaps a more important end point validating the utility of aggressive clinical intervention. The Venous disability score (VDS) is a modification of the original CEAP disability score. It is intended to correlate the patients' symptoms to their daily usual activities. The venous disability score was introduced by the American Venous Forum in 2000. This previously validated venous disability index has been used to quantify degree of disability referable to a patient's venous disease burden reflecting their ability to perform activities of daily living with or without compression and/or elevation.¹⁰

In our study, 82.6% of the patients remained functionally asymptomatic without requiring compression at the end of follow up period of 24 months. Furthermore, 4.4% of the patients were able to perform their activities of daily living with an adjunctive compression support, highlighting that the vast majority of patients undergoing treatment will derive a sustained functional benefit. By comparison, only 13% of the patients were unable to perform their usual activities despite using compression support.

We also used the Villalta scale which is designed to monitor clinical outcome by symptoms and signs which showed a significant improvement both early at one month and late at 24 months of follow up. Thus demonstrating a clear clinical benefit in terms of patients' symptoms and physician observed clinical signs. Again, this highlights and justifies the utility of endovascular intervention for this group of patients. The Villalta scale consists of six clinician-rated physical signs and five patient-rated venous symptoms, of which each are rated on a four-point scale (0= none, 1 = mild, 2 = moderate, 3=severe). Points are summed to produce a total score (range 0-33). Subjects are classified as having post-thrombotic syndrome if the score is ≥ 5 or if a venous ulcer is present in a leg with previous DVT. The Villalta scale was used in several studies to diagnose post thrombotic syndrome (PTS). Score ≥ 5 confirming the diagnosis of PTS, and a score >14 denoting severe PTS. The Villalta scale has also been used as a continuous measurement for longer term follow up to grade the severity of the condition and to assess the effectiveness of treatments.¹¹

The Villalta scale is a validated, reliable method of identifying patients with the post-thrombotic syndrome.¹²

Regarding technical success and durability of the procedure, as measured by patency rates, our study documents good mid-term overall patency after endovascular treatment. Our primary patency was 89.4%, with associated assisted primary patency rates of 100% at 24 months. Loss of primary patency, when it did occur, was observed in the early post-intervention period, with excellent assisted primary patency rates. Thus, aggressive re-intervention for early in-stent stenosis in this patient population may be beneficial, leading to a sustained clinical benefit for the patients.

Our technical results are concordant with other previous studies. In 2007, Neglen et al documented long-term clinical and hemodynamic outcomes in a cohort of 870 patients with chronic venous obstruction. Primary, assisted primary, and secondary patency rates at 72 months were 67%, 89%, and 93%, respectively.⁵ In addition, Hartung et al reported primary, assisted-primary, and secondary patency rates at 36 to 60 months as 73%, 88%, and 90%, respectively, in patients undergoing ilio caval stenting for chronic proximal venous obstruction.¹³ In 2000, O'Sullivan et al reviewed 39 patients with symptomatic iliac vein compression, half with acute DVT, and reported a 1-year patency rate of 79%. Nearly, all (97%) patients in this series experienced symptomatic improvement.¹⁴ Although additional reports also highlight the technical success of aggressive therapy in patients for both acute and chronic indications, few have measured functional outcomes in both acute and chronic settings. Accordingly, our study attempts to better define the functional outcomes following iliofemoral venous stenting.

Another important issue that needs to be highlighted in our study is the applicability of extending venous stents below the inguinal ligament to involve the common femoral vein. Although in our study the two cases of in-stent stenosis were observed in two out of four patients in whom the stents were extended below the inguinal ligament, we think that this in-stent stenosis was related to the severity of post-thrombotic occlusion in these patients rather than due to the fact of mere extension of the stents to the below the inguinal ligament venous segment.

This was also supported by the opinion of Neglen et al, who stated that *"Contrary to arterial stenting, braided stainless stents can be safely placed in the venous system across the inguinal crease with no risk of stent fractures, narrowing due to external compression, or focal development of severe in-stent restenosis. Patency of these stents is not associated with the sub-inguinal site of placement, but is related to the etiology of the obstruction with secondary patency depending on the severity of post-thrombotic obstruction. It is vital to ensure adequate inflow and outflow of the stented vein by covering the entire iliofemoral obstructive lesion, even though this may entail crossing the hip joint. Failure to extend the stent under these circumstances creates a higher risk of stent occlusion than does the stent extension itself"*.¹⁵

This study has an intrinsic limitation of being modest in size, yet it still represents one of the very few series to date documenting post-intervention functional outcomes. Despite these limitations, this series does successfully document good durability and functional improvement in a real-world experience at a tertiary care center.

In conclusion, this study successfully demonstrates a durable 2-years primary, and assisted primary patencies among patients treated for chronic post-thrombotic iliofemoral venous occlusive disease. Furthermore, those patients derived sustained symptomatic relief and significant improvement in their venous disability scores, with the majority of patients able to resume their activities of daily living. Therefore, aggressive endovascular therapy in patients with chronic post-thrombotic iliofemoral venous occlusive disease provides durable patency as well as significant clinical improvement. Those patients, many of whom are young, can anticipate an excellent functional recovery with a high likelihood of returning to work.

REFERENCES

1. Courtney J. Warner, Philip P. Goodney, Jessica B. Wallaert, Brian W. Nolan, Eva M. Rzcudlo, Richard J. Powell, Daniel B. Walsh, and David H. Stone. Functional Outcomes Following Catheter-Based Iliac Vein Stent Placement. *Vascular and Endovascular Surgery* 2013; 47(5): 331-334
2. Delis KT, Bountouroglou D, Mansfield AO. Venous claudication in iliofemoral thrombosis: long-term effects on venous hemodynamics, clinical status, and quality of life. *Ann Surg* 2004; 239:118-26.
3. Comerota AJ, Throm RC, Mathias SD, Haughton S, Mewissen M. Catheter-directed thrombolysis for iliofemoral deep venous thrombosis improves health-related quality of life. *J Vasc Surg* 2000; 32:130-137.
4. Vedantham S. Valvular dysfunction and venous obstruction in the post-thrombotic syndrome. *Thromb Res* 2009; 123(Suppl. 4): S62-S65.
5. Neglén P, Hollis K, Olivier J, Raju S. Stenting of the venous outflow in chronic venous disease: Long-term stent-related outcome, clinical, and hemodynamic result. *Journal of vascular surgery* 2007; Volume 46(5): 979-990
6. Vogel D, Comerota A, Al-Jabouri M, and Zakaria I. Common femoral endovenectomy with ilio caval endoluminal recanalization improves symptoms and quality of life in patients with postthrombotic iliofemoral obstruction. *Journal of vascular surgery* 2012; Volume 55(1): 129-135
7. Crisostomo P, Jenny Cho, Feliciano B, Klein J, Jones D, and Dalsing M. Period frequency of iliofemoral venous occlusive disease by Doppler ultrasound and corresponding treatment in a tertiary care facility. *Journal of vascular surgery* 2010; Volume 52(5): 1272-1277
8. Rosales A, Sandbæk G, Jørgensen JJ. Stenting for Chronic Post-thrombotic Vena Cava and Iliofemoral Venous Occlusions: Mid-term Patency and Clinical Outcome. *Eur J Vasc Endovasc Surg* 2010; 40: 234-240
9. Eklöf B, Rutherford RB, Bergan JJ, Carpentier PH, Gloviczki P, Kistner RL, et al. Revision of the CEAP classification for chronic venous disorders: consensus statement. *J Vasc Surg* 2004; 40:1248-52
10. Rutherford RB, Padberg FT, Comerota AJ, Kistner RL, Meissner MH, Moneta GL. Venous severity scoring: An adjunct to venous outcome assessment. *J Vasc Surg.* 2000;31(6):1307-1312
11. Soosainathan A, Moore H, Gohel M, Davies A. Scoring systems for the post thrombotic syndrome. *J Vasc Surg* 2013; 57:254-261

12. Kahn SR. Measurement properties of the Villalta scale to define and classify the severity of the post thrombotic syndrome. *J Thromb Haemost* 2009;7:884-8
 13. Hartung O, Otero A, Boufi M, Decaridi G, Barthelemy P, Juhan C, et al. Mid-term results of endovascular treatment for symptomatic chronic nonmalignant ilio caval venous occlusive disease. *J Vasc Surg.* 2005;42(6):1138-1144.
 14. O'Sullivan GJ, Semba CP, Bittner CA, et al. Endovascular management of iliac vein compression (May-Thurner) syndrome. *J Vasc Interv Radiol.* 2000;11(7):823-836.
 15. Neglén P, Paul Tackett T, and Raju S. Venous stenting across the inguinal ligament. *J Vasc Surg* 2008;48:1255-61.
-